

The spectrum of renal tubular acidosis in paediatric Sjögren syndrome

F. Pessler¹, H. Emery⁴, L. Dai⁵, Y.-M. Wu⁵, B. Monash³, R. Q. Cron^{1,3,†} and M. Pradhan^{2,3,†}

Objectives. Renal tubular acidosis (RTA) is a well-recognized extraglandular complication of adult Sjögren syndrome (SS) but has been reported only rarely in paediatric SS. We wished to describe the natural history of RTA in paediatric SS.

Methods. We performed a chart and literature review. Inclusion criteria were primary or secondary SS with onset before 18 yr of age, complicated by RTA before 18 yr of age.

Results. Twelve cases were identified: two from chart review and 10 from the literature. RTA was mostly associated with primary SS. RTA was detected at the onset of SS or up to 9 yr later. The clinical spectrum ranged from nearly silent to life-threatening, with plasma pH and serum potassium as low as 7.0 and 1.2 mEq/l, respectively. Hypokalaemia was present in 92%. Half the patients presented with profound weakness or paralysis, most likely from hypokalaemia. Proximal, distal and mixed RTA were detected, reflecting a diffuse ‘tubulopathy’ from interstitial nephritis, which was the predominant histopathological finding. Diabetes insipidus was the most frequent renal comorbidity. The RTA stabilized in 82% of the cases and resolved in one case. Only one patient had long-term unstable RTA.

Conclusions. RTA is an under-recognized complication of paediatric SS. It can be life-threatening in the acute phase but generally has a good long-term renal outcome. SS should be considered in the older child with otherwise unexplained RTA. Likewise, RTA should be excluded in children and adolescents with SS who develop weakness, fatigue or growth failure. Early recognition would reduce long-term complications such as growth failure.

KEY WORDS: Growth failure, Paediatric Sjögren syndrome, Renal tubular acidosis, Sjögren syndrome.

Sjögren syndrome (SS) is a chronic autoimmune disorder affecting primarily the salivary and lachrymal glands, where severe involvement ultimately leads to the sicca syndrome (xerophthalmia and xerostomia). In addition, disease activity in other organs can lead to inflammatory changes in, for instance, the lung, liver, kidneys, pancreas, skin and central nervous system. These extraglandular manifestations have been studied best in adult-onset SS, but several reports have also documented significant extraglandular involvement in paediatric SS [1–3]. However, because they are so rare in the paediatric population, most extraglandular manifestations of paediatric SS have not been studied systematically, and diagnosis and management are usually inferred from experience with adult patients.

Renal tubular acidosis (RTA) is commonly divided into three major types [4]. Proximal RTA results from defective bicarbonate reabsorption in the proximal tubule, whereas distal RTA is the consequence of impaired hydrogen ion secretion in the distal tubule. A non-anion gap metabolic acidosis with inadequate urine acidification and variable degrees of hypokalaemia is the clinical hallmark of both. Mixed forms with features of both occur also, albeit less frequently [e.g. 5, 6]. The RTA secondary to mineralocorticoid deficiency is distinguished by the presence of hyperkalaemia. Growth failure and rickets are long-term complications of RTA in paediatric patients. RTA is a well-recognized extraglandular complication of adult SS [7, 8], but has been

described in paediatric SS only in a small number of isolated reports. We therefore wished to describe the natural history of paediatric SS-associated RTA. Here, we report two cases of severe RTA associated with paediatric SS and summarize the clinical features of these and 10 cases extracted from the international literature.

Methods

Retrospective chart and literature review

Inclusion criteria were primary or secondary SS with onset before 18 yr of age, complicated by RTA before 18 yr of age. We reviewed clinic charts of 15 patients diagnosed at the Children’s Hospital of Philadelphia with SS since 1993. One case of RTA was identified. One of the authors (H.E.) contributed another unpublished case from her institution. The electronic databases Medline, PubMed, and Science Citation Index were searched using the terms ‘tubular acidosis’ and ‘Sjögren’ or ‘Sjögren’s’, restricting age to 0–18 yr. We suspected that cases published in Chinese might not be identifiable in these databases and therefore performed an identical search using the Chinese National Knowledge Infrastructure, CNKI (available at <http://www.cnki.net>). Eleven reports were found [3, 9–18]: four in CNKI and seven in the other databases, but two of the latter featured

Department of Pediatrics, Divisions of ¹Rheumatology and ²Nephrology, The Children’s Hospital of Philadelphia, ³University of Pennsylvania School of Medicine, Philadelphia, PA, ⁴Division of Rheumatology, Children’s Hospital and Regional Medical Center, Seattle, WA, USA and ⁵Division of Rheumatology, Department of Internal Medicine, The 2nd Affiliated Hospital, Sun Yat-sen University, Guangzhou 510120, People’s Republic of China.

†These two authors contributed equally.

Received 22 May 2005; revised version accepted 9 August 2005.

Correspondence to: F. Pessler, Department of Pediatrics, Division of Rheumatology, The Children’s Hospital of Philadelphia, 3405 Civic Center Boulevard, Philadelphia, PA 19104, USA. E-mail: pessler@email.chop.edu

the same patient [9, 14]. No additional cases were found in the reference lists of these reports and in the published case series of paediatric SS. This suggested that the 1969 article by Shioji *et al.* [9] was the first report of RTA in paediatric SS accessible by current bibliographic searching tools. We obtained additional follow-up information for Cases 2, 7 and 10 by contacting the authors.

This study was approved by the Institutional Review Board of the Children's Hospital of Philadelphia and complied with the standards currently applied in the USA. Patient consent was waived because no personally identifiable data were used.

Report of two cases

Case A (Table 1, Case 11). An 8-month-old African American girl presented with purpura. Polyarthritis and uveitis were noted at 12 months. Laboratory results included: white blood cell count 16 300/mm³, haemoglobin 9.5 mg/dl, platelets 689 000/mm³, 36% neutrophils, 63% lymphocytes, 1% monocytes, erythrocyte sedimentation rate (ESR) 106 mm/h, anti-nuclear antibodies (ANA) positive (titre, 1:320), and rheumatoid factor (RF) negative. Immunoglobulin (Ig) G, IgM and IgA were elevated at 2150, 275 mg/dl and 194 mg/dl, respectively. Complement levels and urinalysis were normal. Treatment with NSAIDs, topical and systemic corticosteroids and methotrexate (0.5 mg/kg subcutaneously) was initiated for presumed polyarticular juvenile rheumatoid arthritis (JRA) with JRA-associated uveitis. Severe dental caries developed in early primary teeth, and a tooth abscess required extraction. An eye examination at 2 yr revealed bilateral uveitis with 360° posterior synechiae. The ocular course was further complicated by optic neuritis before age 3 yr and bilateral exudative retinal detachment. Polyarthritis of fluctuating severity continued throughout childhood, requiring frequent adjustment of corticosteroid dosing and increasing the methotrexate to 1 mg/kg/week at age 9 yr. Laboratory evaluation at 10 yr revealed: positive ANA (titre 1:1280) but undetectable anti-SS-A/SS-B antibodies and RF. Serum bicarbonate and potassium levels had been tested regularly as part of routine laboratory evaluations and were always normal. Infliximab (initially 3 mg/kg every 4 weeks and later 5 mg/kg every 3 weeks) was started at age 10 yr for worsening polyarthritis despite increasing methotrexate to 1 mg/kg/week. Seven months after starting infliximab, the patient presented to an outside hospital with altered mental status, profound weakness and abdominal pain. Profound hypokalaemic acidosis was detected, with arterial blood gas analysis showing pH 7.0, carbon dioxide 41 mmHg, oxygen 71 mmHg, base excess -16 mEq/l, and serum potassium 1.2 mEq/l and bicarbonate 9.5 mEq/l. Upon transfer to our institution, laboratory tests included: arterial pH 7.12, sodium 146 mEq/l, potassium 1.6 mEq/l, chloride 122 mEq/l, bicarbonate 12 mEq/l, creatinine 0.7 mEq/l, phosphate 3.5 mEq/l and magnesium 2.2 mEq/dl. Urinalysis revealed pH 6.5, Na⁺ 140 mEq/l, K⁺ 4.7 mEq/l, generalized aminoaciduria without glycosuria, and transient, mild proteinuria. There were no urine casts. The presence of a normal anion gap acidosis with inadequate urine acidification and fulminant aminoaciduria was consistent with a diagnosis of proximal RTA. The patient was intubated and placed on respiratory support because of severe acidosis. She stabilized on high-dose intravenous methylprednisolone (30 mg/kg daily for 3 days) and intravenous potassium and bicarbonate supplementation. Xerostomia and severe dental caries were noted. A minor salivary gland biopsy revealed periductal lymphocytic, histiocytic and plasma cell infiltrates (focus score 2), consistent with SS. Hydroxychloroquine (200 mg daily) was added. A 9-month corticosteroid taper was tolerated well. The proteinuria resolved after 4 months. At four years of follow-up, the patient is on stable doses of hydroxychloroquine (200 mg daily), methotrexate (25 mg/kg subcutaneously weekly) and etanercept (25 mg/kg subcutaneously twice weekly). Her arthritis responded remarkably

well to TNF- α blockade, with disappearance of tender and swollen joints and subjective report of highly improved well-being and functioning. Urinalyses and serum creatinine levels have been normal. In contrast, her renal tubular dysfunction appears unchanged, as evidenced by stable requirements for oral sodium citrate (3 mEq/kg per 24 h), potassium (3 mEq/kg per 24 h) and phosphate supplementation.

Case B (Table 1, Case 12). A 6-yr-old girl was seen by her primary doctor for 'mumps' in spite of having been immunized. Her height was 111 cm (10–25th percentile) and her weight 20 kg (50th percentile). History revealed polydipsia and polyuria of uncertain duration. Urine specific gravity was 1.001–4. Later that year she had another episode of parotitis and mild lymphopenia (absolute lymphocyte count 660/mm³). Persistent urine specific gravity of 1.001 was noted. She then developed transient abdominal pain and vomiting, with laboratory tests significant for serum potassium of 2.6 mEq/l, bicarbonate of 17 mEq/l, white blood cell count of 19 000/mm³ and ESR of 52 mm/h. Two years later she developed acute paralysis. Laboratory tests revealed plasma pH 7.18, serum potassium 1.8 mEq/l, bicarbonate 11 mEq/l and urine pH 6.2. An electrocardiogram revealed prolonged QT interval. Her height was 124 cm (below 3rd percentile) and weight 34.6 kg (50th percentile). RTA was diagnosed. Because of illness of a family member, follow-up and adherence to electrolyte supplementation was poor.

She was seen in the rheumatology clinic at 10 yr of age. She described dry mouth, dry eyes and polyuria/polydipsia. Laboratory studies revealed: positive ANA (titre 1:5120), strongly positive RF at 369 U/ml (normal <40 U/ml), positive anti-SS-A and SS-B, negative anti-DNA and anti-Smith antibodies, ESR 39 mm/h, and normal blood urea nitrogen and creatinine. The diagnosis of SS was made. Compliance with treatment and follow-up was again poor. At age 13 yr, she returned to the rheumatology clinic with a 6-week history of hand, neck, shoulder and leg pain, severe enough to cause night awakening. She had multiple tender and swollen joints with limitation of range of movement. A kidney biopsy revealed extensive glomerulosclerosis, mononuclear tubulointerstitial nephritis with interstitial fibrosis and tubular atrophy. Because of the severe renal involvement, she was initially treated with prednisolone and 6-monthly doses of cyclophosphamide. She is currently maintained on mycophenolate mofetil and electrolyte supplementations. There is no evidence of renal insufficiency. Her height remains at the third percentile, although her weight has increased to the 75th percentile. She has not commenced menses at 13 yr of age and has delayed bone age.

Results

Clinical and laboratory characteristics of all cases are shown in Tables 1 and 2.

Reflecting the worldwide nature of this survey, seven patients (58%) were Asian, four patients (33%) Caucasian and one patient (8%) African American. Eleven (92%) patients were female. Results of serological tests were: ANA-positive, 12/12 tested (100%), SS-A-positive, 9/11 (82%), SS-B-positive, 6/11 (55%) and RF-positive, 11/12 (92%) (Fig. 1A). Salivary gland biopsies were performed in eight cases and showed mononuclear peri-acinar inflammation in all cases. Most cases (9, 75%) were associated with primary SS (Fig. 1A). Two patients (Cases 11 and 12) had SS with arthritis. In these cases it was not possible to determine whether they had primary SS with Sjögren arthropathy or secondary SS with JRA, since (i) SS can feature a polyarthritis indistinguishable from that of polyarticular JRA, and (ii) both JRA and SS are associated with positive RF (see reference 19 for a discussion of this diagnostic dilemma). One patient (8%) had secondary SS associated with mixed connective tissue disease. The mean age of SS onset was 9.4 yr (range 1–17 yr), whereas the

TABLE 1. Reports of clinically overt RTA in paediatric SS

	Case											
	1	2 ^h	3	4	5	6	7 ^e	8	9	10	11	12
Reference	[9, 14]	[10]	[15]	[11]	[3]	[12]	[13]	[17]	[18]	[16]	Case A	Case B
Age (yr), ^g sex	14, F	15, F	13, F	15, F	10, F	15, F	10, M	12, F	17, F	14, F	10, F	8, F
Race	Asian	Caucasian	Asian	Asian	Asian	Caucasian	Caucasian	Asian	Asian	Asian	African American	Caucasian
SS type	Primary	Secondary	Primary	Primary	Primary	Primary	Primary	Primary	Primary	Primary	SS with arthritis ^f	SS with arthritis ^f
Ocular involvement ^a	–	–	–	+	+	–	–	–	–	+	–	+
Oral involvement ^b	+	–	+	+	+	+	–	+	+	+	+	+
Time to onset (yr) ^c	4	6	4	9	0 ^d	0	0	1	1 month	5	9	2
RTA type	Proximal	Proximal + distal	n/s	Distal	Distal	Distal	Proximal + distal	n/s	n/s	Distal	Proximal	Proximal + distal
Blood pH	7.26	n/s	n/s	7.19	7.34	7.27	n/s	7.4	7.33	7.25	7.0	7.18
Serum HCO ₃	13.3	17	18.6	10.6	17.7	17.1	n/s	20.6	13.5	10.9	9.6	12
Serum K	2.4	2.9	2.5	1.4	n/s	3.1	'Severe ↓K'	4.0	2.0	1.6	1.2	2.3
Urine pH	6.9–7.1	5	7.5–8.0	7.0	n/s	7.1	n/s	7.5	>6.0	7.5	6.5	6.2
Renal comorbidity	–	Renal insufficiency	DI	DI	Nephrocalcinosis	–	–	–	–	DI	–	–
Presenting symptoms and findings	Growth failure, rickets	Fatigue, anorexia	Polydipsia/polyuria, limb numbness and pain, periodic paralysis	Periodic paralysis	Renal calcification	Gait disturbances	Ileus	Fever, headache, vomiting.	Emesis, dysphagia, limb pain, paralysis	Growth failure, paralysis	Altered mental status, weakness	Growth failure, paralysis
Immunomodulatory treatment	(–)	High-dose MP	n/s	P, I	MP, Cyc	P, Cyc	MP, CsA	P	P	P	MP, P, H	P, Cyc, MMF
Renal outcome	Stabilized	Insufficiency and RTA resolved	n/s	Recurrent paralysis	Stabilized	Stabilized	Unstable	RTA stable, proteinuria resolved	Stable	DI, RTA improved and stable	Stable	Stable
Follow-up (yr)	1.5	9	n/s	3	5	20 months	8	n/s	n/s	1.5	4	5

^aAs determined by clinical findings or Schirmer's test; ^bas determined by clinical findings, biopsy, sialography, or scintigraphy; ^ctime from first symptoms attributable to SS to detection of RTA; ^dRTA detected at onset of SS; ^eadditional information kindly provided by A. Sediva, University Hospital Motol and I. Bartunkova, Institute of Immunology, Charles University, both in Prague, Czech Republic; ^fcould not distinguish between primary SS with arthropathy or JRA with secondary SS; ^gage at detection of RTA; ^hadditional information kindly provided by A. Rosenberg, University of Saskatchewan.

Cyc, cyclophosphamide; CsA, cyclosporin A; DI, diabetes insipidus; H, hydroxychloroquine; K, potassium, MMF, mycophenolate mofetil; MP, methylprednisolone; n/s, not specified; P, prednisolone.

TABLE 2. Results of kidney biopsies

Case 1 [9]	Focal interstitial lymphocyte and plasma cell interstitial infiltrates. Mild increase in mesangial cellularity
Case 2 [10]	Interstitial inflammation and tubulitis with lymphocyte, histiocyte, and plasma cell infiltration. Glomeruli relatively unaffected
Case 5 [3]	Peritubular interstitial nephritis, mostly mononuclear
Case 6 [12]	Interstitial nephritis w. lymphocyte and plasma cell infiltration; fibrosis, hyalinization
Case 9 [18]	Mild segmental mesangial hyperplasia, multiple focal tubular atrophy with protein casts. Multiple focal interstitial infiltrates with monocytes, lymphocytes and plasma cells, arteriole wall thickening
Case 12 (this paper)	Mononuclear tubulointerstitial nephritis, moderate interstitial fibrosis and tubular atrophy, glomerulosclerosis

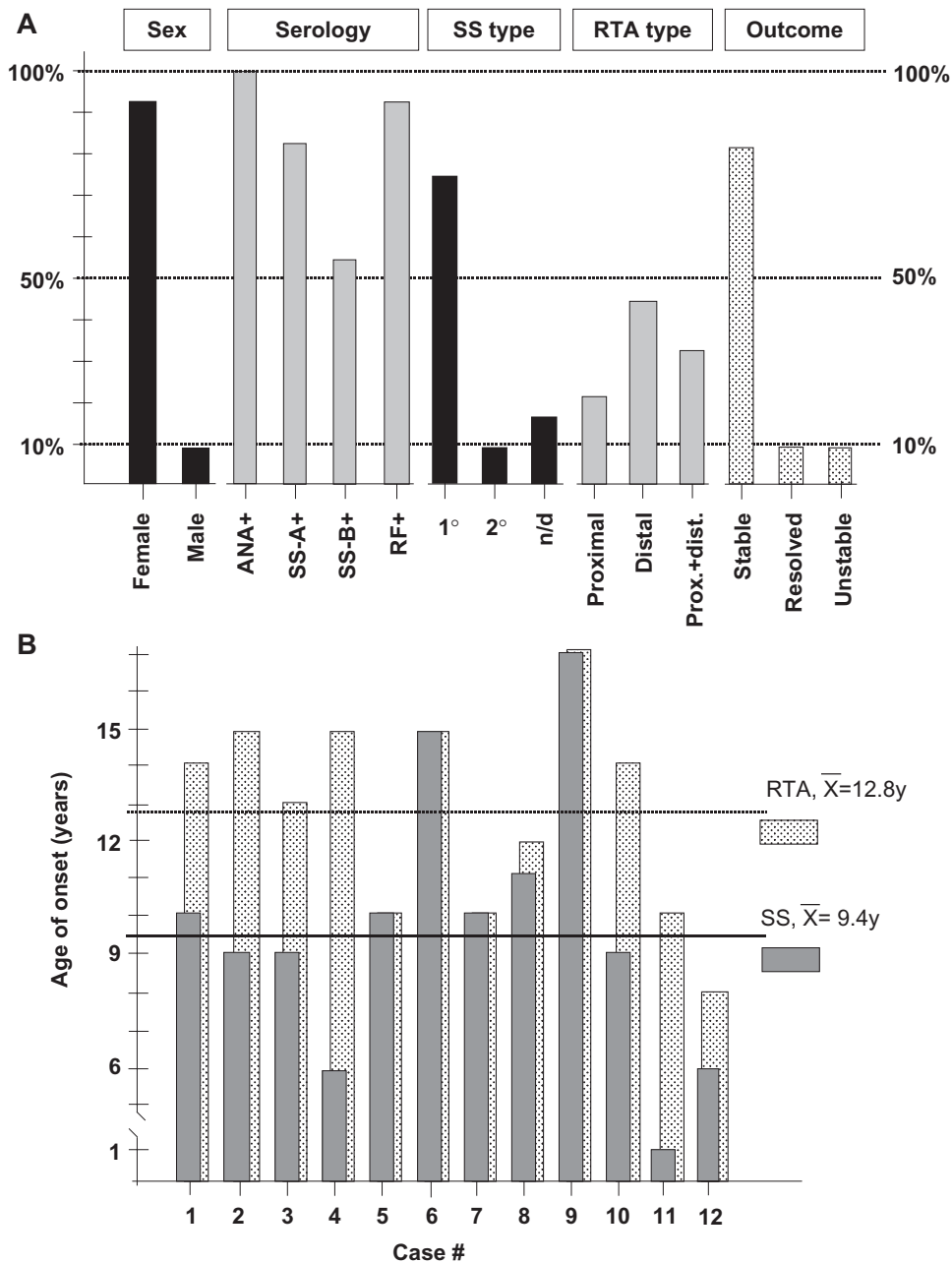


FIG. 1. Summary of demographic, clinical and laboratory results. (A) Percentages of female or male sex, serology results, type of SS, type of RTA, and outcome are indicated by height of the bars. (B) Age of apparent onset of SS and RTA. Solid bars, SS; dotted bars, RTA. Average ages of onset are indicated in the legend on the right. Case #, case number as tabulated in Table 1. (C) Severity of RTA as reflected by plasma pH (lower panel) and serum potassium levels (upper panel). The dotted lines indicate the lower limits of normal. Solid circles, cases with profound weakness/paralysis; open circles, cases without profound weakness/paralysis.

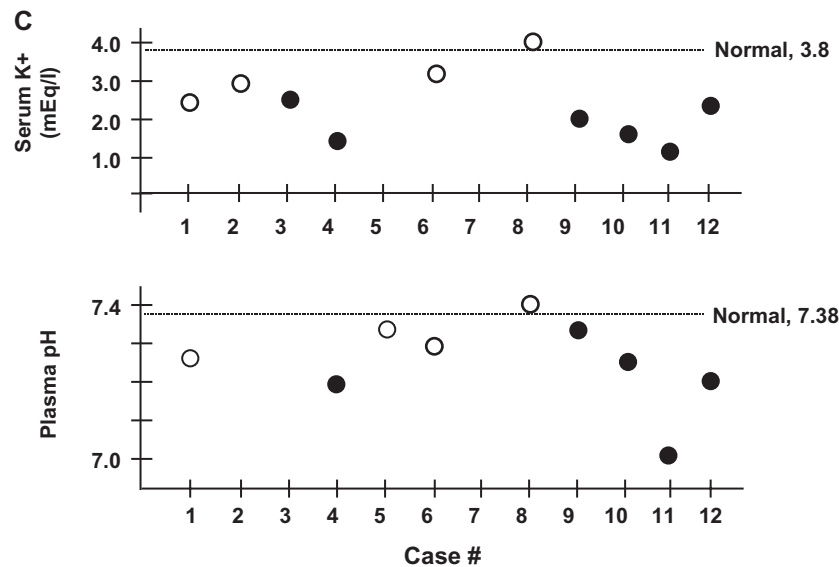


FIG. 1. Continued.

mean age at detection of RTA was 12.8 yr (range 8–17 yr) (Fig. 1B). RTA was present at the onset of SS in three cases (25%), but was detected up to 9 yr later in the others (Fig. 1B). Four out of 12 (33%) had ocular involvement and 10/12 (83%) oral involvement, whereas 2/12 (17%) had neither. The type of RTA could be determined in nine cases and was distal in 4/9 (44%) and proximal in 2/9 (22%), while 3/9 cases (33%) had features of both (Fig. 1A). Hypokalaemia occurred in 11/12 cases (92%). Six patients (50%) presented with profound weakness or paralysis, most likely attributable to hypokalaemia. All cases with paralysis or profound weakness had serum potassium levels ≤ 2.5 mEq/l. Unusual presentations were: failure to thrive of several years' duration before diagnosis of the RTA (Case 1), nephrocalcinosis incidentally detected by radiography (Case 5), hypokalaemic periodic paralysis (Cases 3 and 4) and hypokalaemic ileus (Case 7). Parotid swelling, the most common presenting finding in paediatric SS, was documented in six cases (50%) at some time. The clinical spectrum of the RTA ranged from nearly silent (Case 5) to life-threatening (Case 11). This broad clinical spectrum is also reflected in the widely ranging blood pH (7.0–7.4), and serum bicarbonate (9.6–20.6 mEq/l) and potassium (1.2–4 mEq/l) levels (Fig. 1C). Significant other renal pathology was reported in five cases (42%): diabetes insipidus (DI) in three (25%) and renal failure and nephrocalcinosis in one case each. Proteinuria was present in four cases (33%, Cases 1, 2, 11 and 12), aminoaciduria in two (16%, Cases 1 and 11) and glycosuria in two (16%, Cases 2 and 12). Kidney biopsies (summarized in Table 2) were performed in six patients and revealed mostly interstitial mononuclear infiltrates without significant glomerular changes. Extensive glomerulosclerosis was seen in one case (Case 12) but there was no clinical evidence of renal failure. Treatment information was available in 11 cases. Ten cases (91%) received corticosteroids, and nine (82%) received long-term bicarbonate and/or electrolyte supplements. Hydroxychloroquine was used as adjunct treatment in one patient, whereas three patients received cytotoxic agents. The length of follow-up was determined in 9 cases and ranged from 1.5 to 10 yr. Outcome information was available in 11 cases. The renal outcome was predominantly good. The RTA resolved in one patient (9%) after high-dose corticosteroid treatment and stabilized in nine others (82%). Only one patient (9%) continued to have unstable RTA and required readjustment of

oral or reinstatement of intravenous supplementation at 7 yr of follow-up.

Discussion

RTA in paediatric SS

To verify that the patients in this series were representative of paediatric SS patients, demographic and serological data were recorded (Fig. 1A). Indeed, the observed age of SS onset and sex distribution were close to the values expected in paediatric SS. The rates of ANA, RF and anti-SS-A/SS-B positivity were somewhat higher than in published series [2, 20] but approximate our local experience (manuscript in preparation), suggesting that paediatric SS patients who develop RTA do not form a serologically easily identifiable subgroup. Consistent with this, adults with primary SS and renal involvement display similar serological patterns to those without renal involvement [21]. The fact that parotid gland swelling—the most common presenting finding in paediatric SS—was documented in half the cases further demonstrates that the cases in this series display common features of paediatric SS. Nearly all patients in our series had primary SS, which may be due to reporting or publication bias, although it is also possible that RTA occurs preferentially in primary SS. To our knowledge, this question has not been studied. Interestingly, RTA developed in two patients without lachrymal or salivary involvement, demonstrating that RTA can occur without evident glandular involvement.

The youngest age of RTA onset in our series was 8 yr, whereas primary RTA usually presents in infancy and early childhood. Considering that paediatric SS may present with non-specific symptoms and only rarely features the sicca syndrome, SS should therefore be considered in all older children and adolescents with otherwise unexplained RTA. However, we observed SS onset in the first year of life (Case 11) and RTA was present at the onset of SS in three cases (e.g. Cases 5–7). Thus, SS-associated RTA should be expected in younger children and infants as well. All patients in this series were ANA-positive, but ANA-negative individuals with SS-associated RTA are expected to occur. SS should therefore be excluded by a complete serological evaluation and, if clinically indicated, a salivary gland

biopsy. Proximal and distal RTA were observed, as well as mixed pictures with features of both, suggesting that the renal tubule can be involved anywhere along its length. This probably reflects a diffuse 'tubulopathy' resulting from the interstitial nephritis of SS, which was the predominant biopsy finding (Table 2). Renal failure was rare, but DI was the most frequently associated renal comorbidity and should be excluded in all patients with newly diagnosed SS-associated RTA. It is not clear if the DI was merely the result of hypokalaemia, but it resolved in all cases. None of the patients in this series developed chronic renal failure, but the relatively short follow-up limits this optimistic observation. Publication bias probably influenced the composition of the cases identified through the literature search, since the probability of being published is lower in milder, less unusual cases.

Relationship between paediatric and adult SS-associated RTA

The manifestations of Sjögren nephropathy in adults have been reviewed [22]. Early histopathology shows mostly interstitial nephritis, whereas glomerulonephritis occurs later on. Renal failure is rare, distal and—less frequently—proximal RTA are found, and hyposthenuria is often associated. The RTA varies from asymptomatic or mild to life-threatening [23], can develop several years into the disease course, and 15–30% of adult SS patients are estimated to have subclinical RTA [7, 22]. Most patients respond well to corticosteroids, and cytotoxic agents are currently recommended in cases with significant glomerular involvement or renal vasculitis [24]. These features of adult SS-associated RTA resemble the findings in our paediatric series, suggesting that pathogenesis and natural history of nephropathy and RTA are similar in paediatric and adult SS. Indeed, Bartunkova *et al.* [13] detected asymptomatic RTA in two out of eight patients with paediatric SS, suggesting that it may occur with similar frequency as in adult SS. This also raises the possibility that paediatric patients with newly diagnosed SS should be screened for subclinical RTA.

Instructive aspects of Case A

This patient had the youngest onset of SS. The purpura at age 8 months, severe caries in early primary teeth, and optic neuritis before 3 yr of age suggest onset as early as the first year of life. This patient also presented with the most severe RTA, requiring life support and intravenous electrolyte supplementations. However, she stabilized rapidly on high-dose corticosteroid treatment, and her renal outcome has been good. Interestingly, her RTA developed during infliximab treatment and has remained active despite 4 yr of treatment with TNF- α blockade, thus supporting the notion that TNF- α blockade is ineffective in treating extraglandular manifestations of primary SS [25–27]. The correct diagnosis of paediatric SS is frequently delayed. In this patient, the RTA was recognized as a manifestation of SS and led to the correct diagnosis of SS approximately 9 yr after its presumed onset.

In summary, like the RTA in adult SS, paediatric SS-associated RTA spans the spectrum from an indolent subclinical process to severe, life-threatening hypokalaemic acidosis. The primary treatments are administration of corticosteroids to reduce SS-associated inflammation and bicarbonate/electrolyte supplementation to replace renal losses, while chronic immunosuppressive and/or cytotoxic agents should probably be reserved for cases with more severe renal histological changes such as glomerular involvement (e.g. Case 12). SS should be considered in the differential diagnosis of RTA in the older child, and DI should be ruled out once SS is diagnosed. Vice versa, RTA should be excluded in the paediatric SS patient with persistent weakness,

fatigue or growth failure. In both scenarios, early diagnosis and treatment would help prevent long-term systemic complications such as growth failure.

<i>Rheumatology</i>	Key messages
	<ul style="list-style-type: none"> • RTA in paediatric Sjögren syndrome can be life-threatening in the acute stage but the long-term renal outcome is usually good. • Early recognition and treatment would reduce long-term systemic complications such as growth failure and rickets. • Sjögren syndrome should be considered in the older child with otherwise unexplained RTA. Likewise, RTA should be excluded in paediatric patients with Sjögren syndrome who develop growth failure, fatigue or weakness/paralysis.

Acknowledgements

We thank B. Atreya, P. Rettig and B. Forbes for helpful discussions, K. Meyers for helpful discussion and critical reading of the manuscript, and H. Ebinuma for translating reference 9 from the Japanese. A. Rosenberg, A. Sediva and I. Bartunkova kindly provided additional information about their patients. F.P. was supported by National Institutes of Health Training Grants T32-AR 007442 and T32-CA 09140. R.Q.C. was supported in part by a Nickolett Family Awards Program Grant for JRA Research, the Kahn Foundation for Lupus Research, and a fellowship from the Ethel Brown Foerderer Fund for Excellence. The rheumatological aspects of case 11 have been reported separately [19].

None of the authors declare any conflict of interest.

References

1. Chudwin DS, Daniels TE, Wara DW *et al.* Spectrum of Sjögren syndrome in children. *J Pediatr* 1981;98:213–7.
2. Cimaz R, Casadei A, Rose C *et al.* Primary Sjögren syndrome in the paediatric age: a multicentre survey. *Eur J Pediatr* 2003;162:661–5.
3. Kobayashi I, Furuta H, Tame A *et al.* Complications of childhood Sjögren syndrome. *Eur J Pediatr* 1996;155:890–4.
4. Behrman RE, Kliegman RM, Jenson HB. *Nelson textbook of pediatrics*. Philadelphia: W.B. Saunders, 2003.
5. Hirschman GH, Chan JC. Complex acid-base disorders in subacute necrotizing encephalomyelopathy (Leigh's syndrome). *Pediatrics* 1978;61:278–81.
6. Kodama T, Imai H, Wakui H, Ohtani H, Komatsuda A, Miura AB. Tubulointerstitial nephritis with renal tubular acidosis and asymptomatic primary biliary cirrhosis accompanied by antibody to a 52-kDa mitochondrial protein alone. *Clin Nephrol* 1996;45:401–5.
7. Shearn MA, Tu WH. Latent renal tubular acidosis in Sjögren's syndrome. *Ann Rheum Dis* 1968;27:27–32.
8. Talal N, Zisman E, Schur PH. Renal tubular acidosis, glomerulonephritis and immunologic factors in Sjögren's syndrome. *Arthritis Rheum* 1968;11:774–86.
9. Shioji R, Furuyama T, Onodera S, Katsushima I, Maebashi M. [Case of renal tubular acidosis seen in a 14-year old girl with Sjögren's syndrome]. [Japanese]. *Naika* 1969;23:171–7.
10. Rosenberg AM, Dyck RF, George DH. Intravenous pulse methylprednisolone for the treatment of a child with Sjögren's nephropathy. *J Rheumatol* 1990;17:391–4.

11. Chang YC, Huang CC, Chiou YY, Yu CY. Renal tubular acidosis complicated with hypokalemic periodic paralysis. *Pediatr Neurol* 1995;13:52–4.
12. Zawadzki J. Permeability defect with bicarbonate leak as a mechanism of immune-related distal renal tubular acidosis. *Am J Kidney Dis* 1998;31:527–32.
13. Bartunkova J, Sediva A, Vencovsky J, Tesar V. Primary Sjögren's syndrome in children and adolescents: proposal for diagnostic criteria. *Clin Exp Rheumatol* 1999;17:381–6.
14. Shioji R, Furuyama T, Onodera S, Saito H, Ito H, Sasaki Y. Sjögren's syndrome and renal tubular acidosis. *Am J Med* 1970;48:456–63.
15. Zhang LL, Li L, Lin MY. One case report of pediatric Sjögren syndrome presenting with renal tubular acidosis. [Chinese]. *J Appl Clin Pediatr* 1994;9:310–1.
16. Liu DM, Li M-Z. A case of primary Sjögren syndrome. [Chinese]. *J App Clin Pediatr* 2003;8:45.
17. Shi Q-S, He X-X. A case of primary Sjögren syndrome. *Chin J Birth Health Hered* 2001;9:102.
18. Zeng Y, Huang W, Wang L-Zea. A case report of pediatric Sjögren syndrome presenting with renal tubular acidosis. [Chinese]. *Clin Focus* 2002;17:355.
19. Pessler F, Monash B, Rettig P, Forbes B, Kreiger PA, Cron RQ. Sjögren syndrome in a child: favorable response of the arthritis to TNF α blockade. *Clin Rheumatol* 2005, in press.
20. Nikitakis NG, Rivera H, Lariccia C, Papadimitriou JC, Sauk JJ. Primary Sjögren syndrome in childhood: report of a case and review of the literature. *Oral Surg Oral Med Oral Pathol Oral Radiol Endod* 2003;96:42–7.
21. Garcia-Carrasco M, Ramos-Casals M, Rosas J *et al.* Primary Sjögren syndrome: clinical and immunologic disease patterns in a cohort of 400 patients. *Medicine (Baltimore)* 2002;81:270–80.
22. Skopouli FN. Kidney injury in Sjögren's syndrome. *Nephrol Dial Transplant* 2001;16(Suppl. 6):63–4.
23. Fujimoto T, Shiiki H, Takahi Y, Dohi K. Primary Sjögren's syndrome presenting as hypokalaemic periodic paralysis and respiratory arrest. *Clin Rheumatol* 2001;20:365–8.
24. Brenner BME. Brenner and Rector's *The Kidney*, 7th edn. Philadelphia: W.B. Saunders, 2004.
25. Mariette X, Ravaud P, Steinfeld S *et al.* Inefficacy of infliximab in primary Sjögren's syndrome: results of the randomized, controlled Trial of Remicade in Primary Sjögren's Syndrome (TRIPSS). *Arthritis Rheum* 2004;50:1270–6.
26. Zandbelt MM, de Wilde P, van Damme P, Hoyng CB, van de Putte L, van den Hoogen F. Etanercept in the treatment of patients with primary Sjögren's syndrome: a pilot study. *J Rheumatol* 2004;31:96–101.
27. Sankar V, Brennan MT, Kok MR *et al.* Etanercept in Sjögren's syndrome: a twelve-week randomized, double-blind, placebo-controlled pilot clinical trial. *Arthritis Rheum* 2004;50:2240–5.